Downloaded from www.ajronline.org by 2409:4070:4e06:9a57:2d79:dbf4:513b:956f on 09/21/22 from IP address 2409:4070:4e06:9a57:2d79:dbf4:513b:956f. Copyright ARRS. For personal use only; all rights reserved

Graded Compression Sonography with Adjuvant Use of a Posterior Manual Compression Technique in the Sonographic Diagnosis of Acute Appendicitis

Jong-Hwa Lee[1]
Yoong Ki Jeong
Jae Cheol Hwang
Soo Youn Ham
Seoung-Oh Yang

OBJECTIVE. We evaluated the usefulness of graded compression sonography with the adjuvant use of a posterior manual compression technique for detection of the vermiform appendix and the diagnosis of acute appendicitis.

SUBJECTS AND METHODS. Five hundred seventy consecutive patients referred for suspected acute appendicitis were prospectively examined by original, graded compression sonography with a 5- or a 7.5-MHz linear transducer. A posterior manual compression technique was added for 85 patients whose vermiform appendix was not identified with graded compression sonography. For consensus, another experienced radiologist or a resident observer was in attendance throughout the examination. The detection rate for the vermiform appendix and the diagnostic accuracy for acute appendicitis before and after the adjuvant use of a posterior manual compression technique were obtained, respectively, and final diagnoses were established with the official radiology reports, surgical results, and clinical follow-up.

RESULTS. Graded compression sonography enabled visualization of the vermiform appendix in 485 (85%) of 570 patients. After the adjuvant use of a posterior manual compression technique, the vermiform appendix was found in an additional 57 of 85 patients, with the number of identified vermiform appendices increasing to 542 (95%) of 570 patients. The 57 patients with an additionally found appendix included 11 patients with acute appendicitis. The sonographic diagnosis of acute appendicitis was determined in 312 of 542 patients. Acute appendicitis was proven by surgery in 311 of 332 patients. Sonography was used to establish the diagnosis in 302 of the 311 patients with proven appendicitis; there were 10 false-positive diagnoses and nine false-negative diagnoses. One false-positive diagnosis was acquired after use of the posterior manual compression technique. These results showed more improvement than those of the probabilities for acute appendicitis with single use of graded compression sonography.

CONCLUSION. Graded compression sonography with adjuvant use of a posterior manual compression technique seems to be useful for detecting the vermiform appendix and for diagnosing acute appendicitis.

Graded compression sonography is a major imaging modality for confirming or excluding acute appendicitis [1]. After Puylaert [1] emphasized that sonographic visualization of the vermiform appendix was the sole indicator for diagnosis of acute appendicitis in the original description of graded compression sonography, many studies have used graded compression sonography. Earlier reports show varying detection rates for the vermiform appendix with varying sensitivities of 76–96% and specificities of 91–100% [2–12] for acute appendicitis. The detection rate for the normal appendix as described by Rioux [8] was 82%, but in other reports the rate was lower [1–11, 13]. A difficulty in accurately diagnosing or excluding acute appendicitis is that the vermiform appendix cannot always be detected on gray-scale sonographic scans because of limiting factors such as the operator-dependent technique, the retrocecal location of the appendix, and patient obesity [14]. CT and MR imaging have been used in cases of low-quality sonographic images, and more recently, thin-section helical CT has been used initially for examining patients with suspected acute appendicitis [14–21].

In our experience, the most frequent causes for the decreasing quality of sonographic imaging using a high-frequency linear transducer in the detection of vermiform appendix were poorly compressible right lower quadrant bowel

Received April 9, 2001; accepted after revision October 16, 2001.

[1]All authors: Department of Diagnostic Radiology, Ulsan University Hospital, Ulsan University College of Medicine, 290-3 Junha-Dong, Dong-Gu, Ulsan, 682-060, Korea. Address correspondence to J.-H. Lee.

AJR 2002;178:863–868

0361–803X/02/1784–863

© American Roentgen Ray Society

Downloaded from www.ajronline.org by 2409:4070:4e06:9a57:2d79:dbf4:513b:956f on 09/21/22 from IP address 2409:4070:4e06:9a57:2d79:dbf4:513b:956f. Copyright ARRS. For personal use only; all rights reserved

structures and poor definition of the posterior aspects of the right colon in the obese or muscular body habitus, as well as a retrocecal appendiceal location in which the pertinent structures were located off the depth of view of the sonogram. We present a posterior manual compression technique using the left hand in an attempt to reduce the number of low-quality sonographic images. The background for this technique is forced extrinsic compression of the posterior aspects of the cecum and pericecal space or forced displacement of the right lower quadrant bowel structures onto the psoas muscle using the fingers of the left hand to obtain anterior and posterior simultaneous compression effects. The purpose of our study was to evaluate the usefulness of graded compression sonography with adjuvant use of a posterior manual compression technique for detection of the normal or abnormal vermiform appendix and for the diagnosis of acute appendicitis.

Subjects and Methods

Patients

From July 1998 to June 2000, 570 consecutive patients (age range, 2–85 years; mean age, 34 years), who were suspected of having acute appendicitis on the basis of the clinical judgment of their referring physician, were prospectively examined with sonography in our department. There was no analgesia given to patients before performing the sonographic examination. Two hundred seventy-eight males and 292 females of all ages were included in our study. There were 157 children less than 16 years old (28%). The mean weight of patients admitted to the hospital was 36 kg (range, 12–72 kg) for those less than 16 years old and 64 kg (range, 48–90 kg) for those 16 years old or older. Patients in whom genitourinary diseases were identified were included in this study because we routinely examined the vermiform appendix of patients with all other alternative conditions in our institute. Pregnant patients were excluded from this study because a posterior manual compression technique was not possible.

Sonographic Techniques

All examinations were performed using either a 5- or 7.5-MHz linear transducer (128XP 10; Acuson, Mountain View, CA). All patients were examined in the supine position. A foot switch was used to freeze and print the images when a posterior manual compression technique was used as an adjuvant technique. All sonographic studies were initially performed with transverse and longitudinal graded compression sonography. Graded compression sonography described by Puylaert [1] is composed of anterior forced compression used to reduce the abdominal cavity between the pathologic process and the high-frequency transducer with a short focus. If the vermiform appendix was not visualized after completion of the graded compression scans, a posterior manual compression technique was added in an attempt to further improve detection of the vermiform appendix. This technique is an adjuvant to graded compression sonography and is composed of forced extrinsic compression of the opposite side of the right lower quadrant abdomen in the anterior or anteromedial direction using the palms of the four fingers of the left hand (Fig. 1), thereby allowing compression of the posterior aspects of the cecum or pericecal space with or without anteromedial displacement of the right lower quadrant bowel structures onto the psoas muscle. Therefore, the force of compression and the location of the left hand would be dynamically changed according to suspected colonic parts. This helps to obtain a sufficient depth to be reached by a high-frequency transducer with anterior and posterior simultaneous graded compression, thereby increasing the spatial resolution.

The sonographic approach to the vermiform appendix included sequential visualization of the terminal ileum, ileocecal valve, cecal pole, and orifice of the vermiform appendix. After detecting the orifice of the vermiform appendix, we found that scrupulously tracing the tubular structure of the vermiform appendix to its definite or suspected blind ending was necessary. Sometimes the vermiform appendix is not prone for enough morphologic identification because of poor imaging quality. With these conditions, we tried first to find small, strong reflections adequately made in the appendiceal lumen by gas or feces, which is without peristaltic activity and located in the retroileal or retrocecal area or in other areas. Focused graded compression sonography was performed after continuous or discontinuous strong reflections to help verify the morphology of the vermiform. Axial appendiceal sections were imaged to differentiate the appendix from other compressible bowel loops.

Sonographic Interpretation

One of two gastrointestinal radiologists independently performed the graded compression sono-

Fig. 1.—Photograph shows technique of anterior graded compression sonography with adjuvant use of posterior manual compression technique.

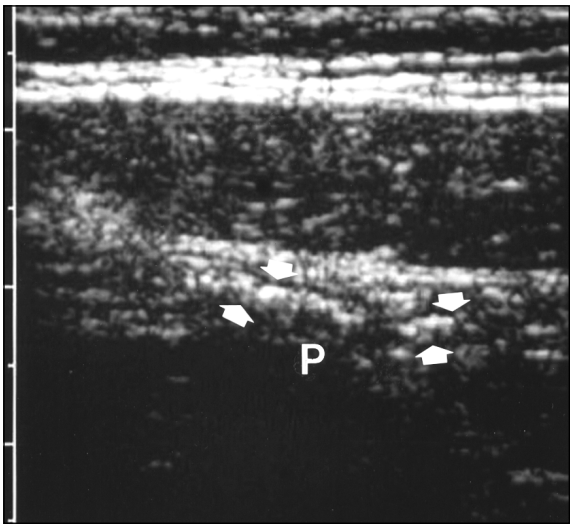

Fig. 2.—51-year-old man with right lower quadrant pain. Graded compression sonogram with adjuvant use of posterior manual compression technique shows compressible tubular structure of normal vermiform appendix (*arrows*) with inner echogenic portion and outer hypoechoic line on iliopsoas muscle (P).

Downloaded from www.ajronline.org by 2409:4070:4e06:9a57:2d79:dbf4:513b:956f on 09/21/22 from IP address 2409:4070:4e06:9a57:2d79:dbf4:513b:956f. Copyright ARRS. For personal use only; all rights reserved

graphic examinations through a region of the right lower quadrant of the abdomen. When it was necessary to obtain consensus for sonographic interpretation after adjuvant use of a posterior manual compression technique, another gastrointestinal radiologist or a resident observer was in attendance throughout the examination.

The establishment of the diagnosis of acute appendicitis was based on the finding of a positive sonographic McBurney sign, a blind-ending tubular structure greater than 6 mm in outer diameter, the noncompressibility of the appendix, the increased flow signals in the appendiceal wall or periappendiceal space using color Doppler sonography, and the echogenic periappendiceal inflammatory fat change. The criteria for a normal appendix were based on a compressible, tubular, blind-ending structure filled with fluid, gas, or feces (Fig. 2). When detecting the vermiform appendix, the following characteristics were noted in the official radiology reports immediately after sonography: the location of the vermiform appendix; the maximum outer appendiceal diameter; the sonographic diagnosis of the appendicitis or alterative diagnoses; and the presence or absence of gross perforation with free gases, phlegmon, or abscess. Nonvisualization of the appendix was interpreted as a negative result.

The sonographic alternative diagnosis in patients with the normal-appearing vermiform appendix was also evaluated, including acute right colonic diverticulitis, mesenteric adenitis, enterocolitis, right ureteral or ureterovesical junction stones, epiploic appendagitis, and acute gynecologic conditions [22–24].

We reviewed the official radiology reports, surgical results, and medical records of 570 patients who underwent surgery for appendicitis or were hospitalized or received clinical follow-up for a nonappendicitis condition.

We calculated the detection rate for the vermiform appendix, sensitivity, specificity, positive and negative predictive values, and diagnostic accuracy for acute appendicitis on graded compression sonography with adjuvant use of a posterior manual compression technique. Probabilities for acute appendicitis with only graded compression sonography were also calculated.

Results

The usual graded compression sonography enabled visualization of the vermiform appendix in 485 (85%) of 570 patients. We then added a posterior manual compression technique to the graded compression sonography in 85 (15%) of 570 patients in whom the vermiform appendix could not be depicted. Graded compression with the adjuvant use of a posterior manual compression technique enabled visualization of the vermiform appendix in an additional 57 (67%) of 85 patients. The number of identified vermiform appendices was increased to 542 (95%) of 570 patients. Locations of the visualized vermiform appendices were retroileal (53%, 287 patients), subcecal (33%, 179 patients), retrocecal–retrocolic (7%, 37 patients), pelvic (5%, 28 patients), preileal, and other (2%, 11 patients). The 57 patients with an additionally identified appendix included 11 patients with acute appendicitis (including six patients with retrocecal appendicitis [Fig. 3] and one patient with a combined ascending colonic diverticulitis and appendicitis) and three patients with a normal vermiform appendix and retrocecal diverticulitis (Fig. 4). Twenty-five of

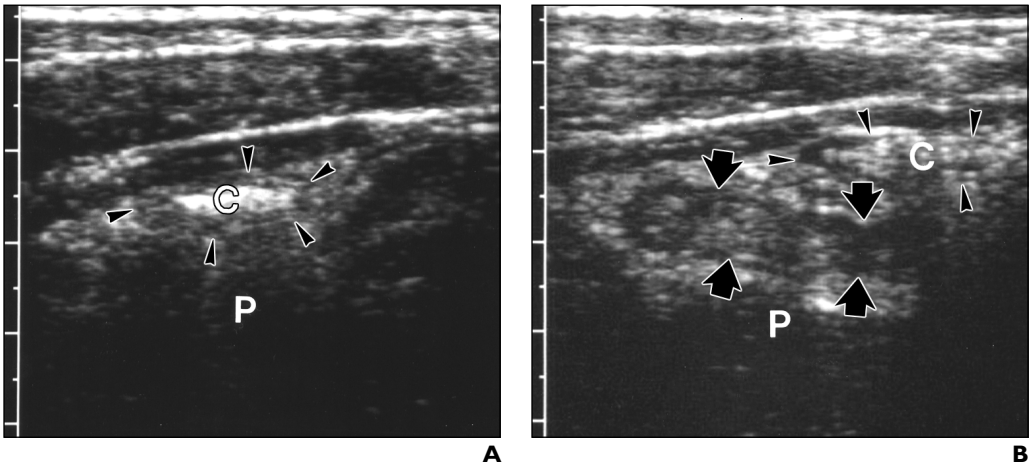

Fig. 3.—21-year-old man with right lower quadrant pain.
A, Graded compression sonogram shows no detectable appendix around cecum (C, *arrowheads*). P = iliopsoas muscle.
B, Graded compression sonogram after adjuvant use of posterior manual compression technique shows clearly visible thickened appendix (*arrows*) at retrocecal location with forced compression of retrocecal space with forced medial displacement of cecum (C, *arrowheads*). Acute appendicitis is surgically confirmed. P = iliopsoas muscle.

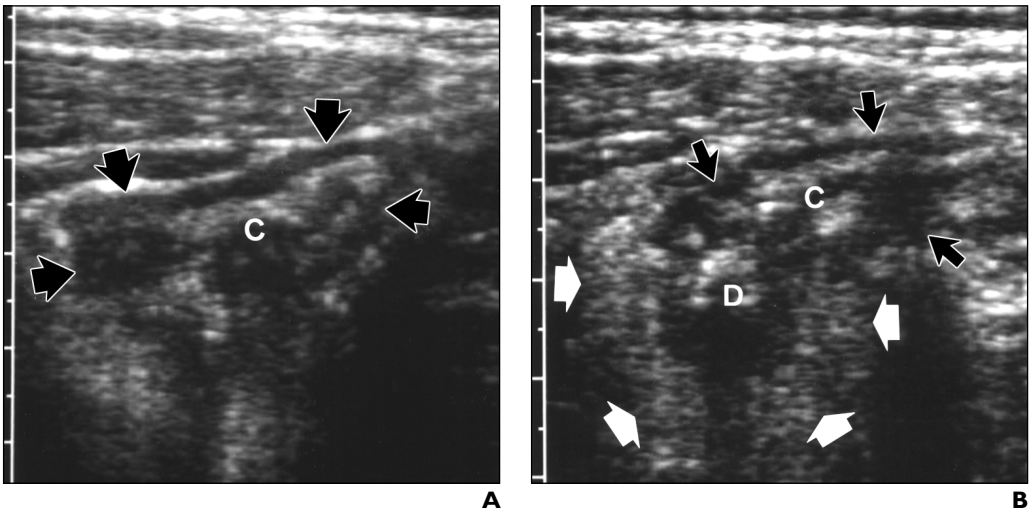

Fig. 4.—52-year-old man with right lower quadrant pain.
A, Graded compression sonogram shows irregular inflammatory wall thickening of cecum (c, *arrows*).
B, Graded compression sonogram after adjuvant use of posterior manual compression technique shows well-defined outpouching of acute diverticulitis (D) at retrocecal location with hyperechoic peridiverticular infiltration (*white arrows*). Black arrows point to cecum (c).

Downloaded from www.ajronline.org by 2409:4070:4e06:9a57:2d79:dbf4:513b:956f on 09/21/22 from IP address 2409:4070:4e06:9a57:2d79:dbf4:513b:956f. Copyright ARRS. For personal use only; all rights reserved

the 57 appendices that were detected after the posterior manual compression technique were located in the retrocecal–retrocolic region, 18 were in the retroileal region, and 14 were in the subcecal region. The sonographic diagnosis of acute appendicitis was determined in 312 of 542 patients. In the remaining 230 of 542 patients with a normal-appearing vermiform appendix, alternative diagnoses were sonographically made in 37 patients with acute right colonic diverticulitis, 122 patients with mesenteric adenitis or enterocolitis, 11 patients with right lower ureteral or ureterovesical junction stones, one patient with epiploic appendagitis, and five patients with right ovarian cystic rupture or hemorrhage. A definite diagnosis for acute appendicitis was confirmed both surgically and histologically in 332 patients. The time interval between the sonographic examination and the surgery was a mean of 5 hr (range, 3–9 hr). Acute appendicitis was proven in 311 of 332 patients. Sonography established the diagnosis in 302 of the 311 patients with proven appendicitis; there were 10 patients with false-positive results and nine patients with false-negative results. One false-positive result was acquired after use of the posterior manual compression technique.

Graded compression sonography with adjuvant use of a posterior manual compression technique yielded a detection rate of 95% (542/570) for the vermiform appendix (normal vermiform appendix, 87%) and a sensitivity of 97% (302/311); a specificity of 96% (249/259); positive and negative predictive values of 97% (302/312) and 97% (249/258), respectively; and an accuracy of 97% (551/570) for acute appendicitis (Table 1). Probabilities for acute appendicitis with only graded compression sonography yielded a detection rate of 85% (485/570) for the vermiform appendix (normal vermiform appendix, 67%); a sensitivity of 94% (292 /311); a specificity of 96% (250/259); positive and negative predictive values of 97% (292/301) and 93% (250/269), respectively; and an accuracy of 95% (542/570) (Table 2). The results of graded compression sonography with adjuvant use of a posterior manual compression technique showed more improvement than those of the probabilities for acute appendicitis with single use.

Discussion

Graded compression sonography primarily consists of anterior forced compression to reduce the distance between the pathologic process and the high-frequency transducer with a short focus and to displace or compress bowel structures to eliminate gas artifacts. Reducing the abdominal cavity enables clear visualization of the retroperitoneal structures [1]. Since Puylaert [1] emphasized that sonographic visualization of the appendix was the sole indicator for diagnosis of acute appendicitis in his original description of graded compression sonography, many studies have used graded compression sonography for a diagnosis of appendicitis with sensitivities and specificities of more than 90% if an experienced examiner performed the examination [2–12]. Graded compression sonography is an established imaging modality in the clinical setting of acute right lower abdominal pain or for the diagnosis of acute appendicitis because of its rapidity, noninvasiveness, real-time scanning, and technical improvements. However, a problem in accurately diagnosing or excluding acute appendicitis is that the vermiform appendix cannot always be detected on gray-scale sonography because graded compression sonography has limiting factors such as its operator-dependent technique, retrocecal location of the vermiform appendix, and patient obesity [14]. No normal appendices were visualized in Puylaert's study, and the detection rate of the normal appendix in most of the earlier reports [1–7, 9–11, 13, 25] was not mentioned or was relatively infrequent except for the 82% rate described by Rioux [8].

In patients with retrocecal appendix or in patients who are obese, high-frequency transducers may fail to reach the necessary depth; this makes an accurate diagnosis difficult because of the decreased spatial resolution [15]. In an attempt to improve low-quality sonographic imaging, we present a posterior manual compression technique. The purpose of this technique is forced extrinsic compression of the posterior aspects of the colon or pericolic space with or without forced displacement of the right lower quadrant bowel structures onto the psoas muscle through manual compression of the posterior or posterolateral aspects of the right lower quadrant using the fingers of the left hand. Subsequently, graded compression sonography with the adjuvant use of posterior manual compression attempts anterior and posterior squeezing of the right lower quadrant bowel structures by means of the kissing effect of the reciprocal anterior and posterior compression techniques. The depth to reach by a high-frequency transducer may be approached on the retrocecal or retrocolic spaces and on the anterior margin of the psoas space, increasing the spatial resolution.

Our study with adjuvant use of a posterior manual compression technique showed that the detection rate of 94% for the vermiform appendix with a positive predictive value of 97% and a negative predictive value of 96% for the diagnosis of acute appendicitis was superior to the previously reported values. If the estimated probabilities for the diagnosis of

TABLE 1 Diagnostic Accuracy for Acute Appendicitis After Posterior Manual Compression with Graded Compression Sonography

Features	Results
Detection rate of vermiform appendix	95% (542/570)
Cases of sonographic diagnosis of acute appendicitis	58% (312/542)
Cases of surgical diagnosis of acute appendicitis	311/570
True-positive results	302
False-positive results	10
True-negative results	249 (24[a])
False-negative results	9 (4[a])
Sensitivity	97%
Specificity	96%
Positive predictive value	97%
Negative predictive value	97%
Diagnostic accuracy	97%

[a]Cases with nonvisualized appendix.

TABLE 2 Probabilities for Acute Appendicitis with Single Use of Graded Compression Sonography

Features	Results
Detection rate of vermiform appendix	85% (485/570)
Cases of sonographic diagnosis of acute appendicitis	301/485
Cases of surgical diagnosis of acute appendicitis	311/570
True-positive results	292
False-positive results	9
True-negative results	250 (71[a])
False-negative results	19 (14[a])
Sensitivity	94%
Specificity	96%
Positive predictive value	97%
Negative predictive value	93%
Diagnostic accuracy	95%

[a]Cases with nonvisualized appendix.

Downloaded from www.ajronline.org by 2409:4070:4e06:9a57:2d79:dbf4:513b:956f on 09/21/22 from IP address 2409:4070:4e06:9a57:2d79:dbf4:513b:956f. Copyright ARRS. For personal use only; all rights reserved

acute appendicitis after the single use of graded compression sonography are calculated, the detection rate for the vermiform appendix, sensitivity, specificity, positive and negative predictive values, and diagnostic accuracy will be decreased to 85%, 94%, 96%, 97%, 93%, and 95%, respectively. Rettenbacher and Hollerweger [25] pointed out the importance of sonographic detection of the presence or absence of gas characterized by a sharp complete reflection in the appendix as criteria to rule out or confirm acute appendicitis. We have also used a sonographic technique considering such small or linear strong echoes or reflections adequately made in the appendix by gas or feces, which are without peristaltic activity and located in the retroileal or retrocecal areas or in other areas, for those whose appendix is not prone for enough morphologic identification as a result of poor imaging quality. The sonographic detection rate (83%) of the vermiform appendix in patients clinically suspected of having acute appendicitis as calculated by Rottenbacher and Hollerweger is similar to that of our study before adjuvant application of a posterior manual compression technique. A high detection rate of the normal appendix with a high negative predictive value will give surgeons much greater confidence because the clear identification of a normal vermiform appendix may be the single most important criterion, excluding acute appendicitis, for determining whether surgery is indicated. The detection rate of the normal appendix was 87% (226/259) in our study. After excluding acute appendicitis, sonographers can concentrate on alternative appendicitis-mimickers in the right lower quadrant abdomen, such as right colonic diverticulitis, right segmental omental infarction, acute enterocolitis, mesenteric lymphadenitis, epiploic appendagitis, and ureteral calculi [22–24].

After adjuvant use of a posterior manual compression technique, alternative diagnoses were correctly established on the basis of surgery, clinical follow-up, or additional imaging findings in 13 patients, acute appendicitis in 10 patients (retrocecal type in six and acute combined diverticulitis and appendicitis in one), and ascending retrocolic colonic diverticulitis in three patients. Most of the alternative diagnoses are of diseases located in a deeper anatomic area of the right lower quadrant abdomen. The graded compression technique with adjuvant use of a posterior manual compression technique reaches a greater depth by the high-frequency transducer than does the single use of graded compression sonography and thus increases the spatial resolution of sonography.

Recently, CT and MR imaging have been used to overcome the limitations of sonography for accurately diagnosing acute appendicitis [14–22]. CT evaluation shows relatively high diagnostic accuracy for acute appendicitis, with sensitivities and specificities of 87–99% [16, 17, 20, 21] because it accurately evaluates suspected and unsuspected appendicitis and suggests other possible causes of acute abdominal pain [14]. MR imaging is also reported to be a valuable technique for imaging children and women of childbearing age with acute appendicitis because it is a nonionizing technique and does not necessitate administration of IV contrast agents [15]. We recommended CT in only six patients with equivocal sonographic findings during our study. Four of these patients were diagnosed with acute appendicitis on CT (two with retrocecal perforated appendicitis, one with subcecal distal perforated appendicitis, and one with ascending retroileal appendicitis). Postoperative findings showed two false diagnoses of a gastric ulcer perforation and a cecal tuberculosis with appendiceal involvement. High scores of visualization of the entire vermiform appendix on sonography at our institute result in avoidance of costly additional examinations using other imaging modalities.

Our sonographic examinations were performed using less than state-of-the-art equipment. Perhaps, better results would be yielded using broadband high-frequency transducers and advanced signal processing technologies such as tissue harmonic imaging and real-time sonoCT (compound imaging technology). Of course, compression techniques using state-of-the-art equipment will, but less frequently, be used to decrease the depth of penetration and avoid bowel gases while sonographic waves travel through the human body.

If the vermiform appendix is located just inferior to the posterior iliac crest, a posterior manual compression technique would not be available because of the bony interference. Therefore, the posterior manual compression technique could help detect appendices located superior to the posterior iliac crest. In our data series, the most common locations of the vermiform appendix were retroileal (53%) and subcecal (33%). Approximately two thirds of the vermiform appendices in our study, excluding inferiorly oriented subcecal and pelvic ones, would be available with the manual compression technique. And, not all inferiorly oriented subcecal appendices are located inferior to the iliac crest because the location of the cecum varies. In our study, 25 of the 57 appendices that were detected after the posterior manual compression technique were in the retrocecal–retrocolic location, 18 were in the retroileal location, and 14 were in the subcecal location.

In conclusion, the adjuvant use of posterior manual compression helps the anterior and posterior simultaneous compressions of the right lower quadrant during graded compression sonography to increase spatial resolution. We consider graded compression sonography with adjuvant use of a posterior manual compression technique to be useful for detecting the vermiform appendix and for diagnosing and excluding acute appendicitis, especially in the retrocecal or retrocolic locations.

Acknowledgment

We thank Bonnie Hami, Department of Radiology, University Hospitals of Cleveland, for her editorial assistance in the preparation of this manuscript.

References

1. Puylaert JB. Acute appendicitis: US evaluation using graded compression. *Radiology* **1986**;158:355–360
2. Abu-Yousef MM, Bleicher JJ, Maher JW, Urdaneta LF, Franken EA Jr, Metcalf AM. High-resolution sonography of acute appendicitis. *AJR* **1987**;149:53–58
3. Jeffrey RB Jr, Laing FC, Townsend RR. Acute appendicitis: sonographic criteria based on 250 cases. *Radiology* **1988**;167:327–329
4. Jeffrey RB Jr, Laing FC, Lewis FR. Acute appendicitis: high resolution real-time US findings. *Radiology* **1987**;163:11–14
5. Gaensler EH, Jeffrey RB Jr, Laing FC, Townsend RR. Sonography in patients with suspected acute appendicitis: value in establishing alternative diagnosis. *AJR* **1989**;152:49–51
6. Kang WM, Lee CH, Chou YH, et al. A clinical evaluation of ultrasonography in the diagnosis of acute appendicitis. *Surgery* **1989**;105:154–159
7. Vignault F, Filiatrault D, Brandt ML, Garel L, Grignon A, Ouimet A. Acute appendicitis in children: evaluation with US. *Radiology* **1990**;176:501–504
8. Rioux M. Sonographic detection of the normal and abnormal appendix. *AJR* **1992**;158:773–778
9. Sivit CJ, Newman KD, Boenning DA, et al. Appendicitis: usefulness of US in diagnosis in a pediatric population. *Radiology* **1992**;185:549–552
10. Balthazar EJ, Birnbaum BA, Yee J, Megibow AJ, Roshkow J, Gray C. Acute appendicitis: CT and US correlation in 100 patients. *Radiology* **1994**;190:31–35
11. Hahn HB, Hoepner FU, Kalle T, et al. Sonography of acute appendicitis in children: 7 years experience. *Pedriatr Radiol* **1998**;28:147–151
12. Zielke A, Hasse C, Sitter H, Rothmund M. Influ-

Downloaded from www.ajronline.org by 2409:4070:4e06:9a57:2d79:dbf4:513b:956f on 09/21/22 from IP address 2409:4070:4e06:9a57:2d79:dbf4:513b:956f. Copyright ARRS. For personal use only; all rights reserved

ence of ultrasound on clinical decision making in acute appendicitis: a prospective study. *Eur J Surg* **1998**;164:201–209
13. Sivit CJ. Diagnosis of acute appendicitis in children: spectrum of sonographic findings. *AJR* **1993**;161:147–152
14. Curtin KR, Fitzgerald SW, Nemcek AA Jr, Hoff FL, Vogelzang RL. CT diagnosis of acute appendicitis: imaging findings. *AJR* **1995**;164:905–909
15. Hormann M, Paya K, Eibenberger K, et al. MR imaging in children with nonperforated acute appendicitis: value of unenhanced MR imaging in sonographically selected cases. *AJR* **1998**;171: 467–470
16. Balthazar EJ, Megibow AL, Siegel SE, Birnbaum BA. Appendicitis: prospective evaluation with high-resolution CT. *Radiology* **1991**;180:21–24
17. Malone AJ Jr, Wolf CR, Malmed AS, Melliere BF. Diagnosis of acute appendicitis: value of unenhanced CT. *AJR* **1993**;160:763–766
18. Rao PM, Rhea JT, Novelline RA, et al. Helical CT technique for the diagnosis of appendicitis: prospective evaluation of a focused appendix CT examination. *Radiology* **1997**;204:139–144
19. Friedland JA, Siegel MJ. CT appearance of acute appendicitis in childhood. *AJR* **1997**; 168:439–442
20. Funaki B, Grosskreutz SR, Funaki CN. Using unenhanced helical CT with enteric contrast material for suspected appendicitis in patients treated at a community hospital. *AJR* **1998**;171:997–1001
21. Lane MJ, Liu DM, Huynh MD, Jeffrey RB Jr, Mindelzun RE, Katz DS. Suspected acute appendicitis: nonenhanced helical CT in 300 consecutive patients. *Radiology* **1999**;213:341–346
22. Birnbaum BA, Jeffrey RB Jr. CT and sonographic evaluation of acute right lower quadrant abdominal pain. *AJR* **1998**;170:361–371
23. Puylaert JB. Mesenteric adenitis and acute terminal ileitis: US evaluation using graded compression. *Radiology* **1986**;161:691–695
24. Puylaert JB, Lalisang RI, van der Werf SD, Doornbos L. Campylobacter ileocolitis mimicking acute appendicitis: differentiation with graded-compression US. *Radiology* **1988**;166: 737–740
25. Rettenbacher T, Hollerweger A, Macheiner, et al. Presence or absence of gas in the appendix: additional criteria to rule out or confirm acute appendicitis—evaluation with US. *Radiology* **2000**; 214:183–187

The full text and images from the *American Journal of Roentgenology* may also be viewed online at www.arrs.org or www.ajronline.org.